



## Demonstrating the interference of tissue processing in the evaluation of tissue biomarkers: The case of PD-L1

Ana Caramelo<sup>a</sup>, António Polónia<sup>a,b</sup>, João Vale<sup>a</sup>, Mónica Curado<sup>a</sup>, Sofia Campelos<sup>a</sup>,  
Vanessa Nascimento<sup>a</sup>, Mariana Barros<sup>a</sup>, Diana Ferreira<sup>a</sup>, Tânia Pereira<sup>a</sup>, Beatriz Neves<sup>a</sup>,  
Catarina Eloy<sup>a,b,c,\*</sup>

<sup>a</sup> Pathology Laboratory, Institute of Molecular Pathology and Immunology of University of Porto (Ipatimup), Porto, Portugal

<sup>b</sup> Instituto de Investigação e Inovação em Saúde (i3S), Porto, Portugal

<sup>c</sup> Faculty of Medicine of University of Porto (FMUP), Porto, Portugal

### ARTICLE INFO

#### Keywords:

PD-L1  
Immunohistochemistry  
Tissue processing

### ABSTRACT

The immunohistochemical (IHC) expression of PD-L1 in cancer models is used as a predictive biomarker of response to immunotherapy. We aimed to evaluate the impact of the usage of 3 different tissue processors in the IHC expression of PD-L1 antibody clones: 22C3 and SP142. Three different topographies of samples (n = 73) were selected at the macroscopy room: 39 uterine leiomyomas, 17 placentas and 17 palatine tonsils. Three fragments were collected from each sample and were inked with a specific color that represented their separate processing in a different tissue processor (A, B or C). During embedding, the 3 fragments with distinct processing were ensemble in the same cassette for sectioning of 3 slides/each: hematoxylin-eosin, 22C3 PDL1 IHC staining and SP142 PD-L1 IHC staining, that were blindly observed by 2 pathologists under digital environment.

All but one set of 3 fragments were considered adequate for observation even in the presence of artifacts associated with processing issues that were recorded as high as 50.7 % for processor C.

The occurrence of background non-specific staining and the presence of false positive results appear to be unrelated with the PD-L1 clone or the type of tissue processing.

22C3 PD-L1 was more frequently considered adequate for evaluation than SP142 PD-L1 that, in 29.2 % of WSIs (after tissue processor C) were considered not adequate for observation due to lack of the typical pattern of expression. Similarly, the intensity of PD-L1 staining was significantly decreased in fragments processed by C (both PD-L1 clones) in tonsil and placenta specimens, and by A (both clones) in comparison with those processed by B.

This study demonstrates the need to standardize the tissue processing in pathology to cope with the growing needs of precision medicine quantifications and the production of high-quality material necessary for computational pathology usage.

### 1. Introduction

Tissue processing in Pathology laboratories had no major modifications during the last decades. The conception of the tissue processing model was designed, many years ago, to fill the needs of laboratories with a less intense daily income of samples and a less demanding precision on the results [1]. Today, we understand that the reported issues [2] related with tissue processing demand a review of this process so that pathologists keep with the high levels of good practice [1,2], coping with the precision requested to evaluated tissue biomarkers [3] or even

assure the standardized quality of material for computational analysis [4].

The immunohistochemical expression of PD-L1 in selected human cancer models such as non-small cell lung carcinoma, urothelial carcinoma [5,6], squamous cell carcinoma of the head and neck [7], gastric carcinoma [8,9] and others, is used in clinical practice as a predictive biomarker of response to immunotherapy. The immunohistochemical testing of PD-L1 with specific clones, such as 22C3 or SP142, for determining response to immunotherapy with pembrolizumab [10] or with atezolizumab [11], respectively, has different interpretation

\* Correspondence to: Ipatimup, Rua Júlio Amaral de Carvalho 45, 4200-135 Porto, Portugal.

E-mail address: [catarinaeloy@hotmail.com](mailto:catarinaeloy@hotmail.com) (C. Eloy).

<https://doi.org/10.1016/j.prp.2023.154605>

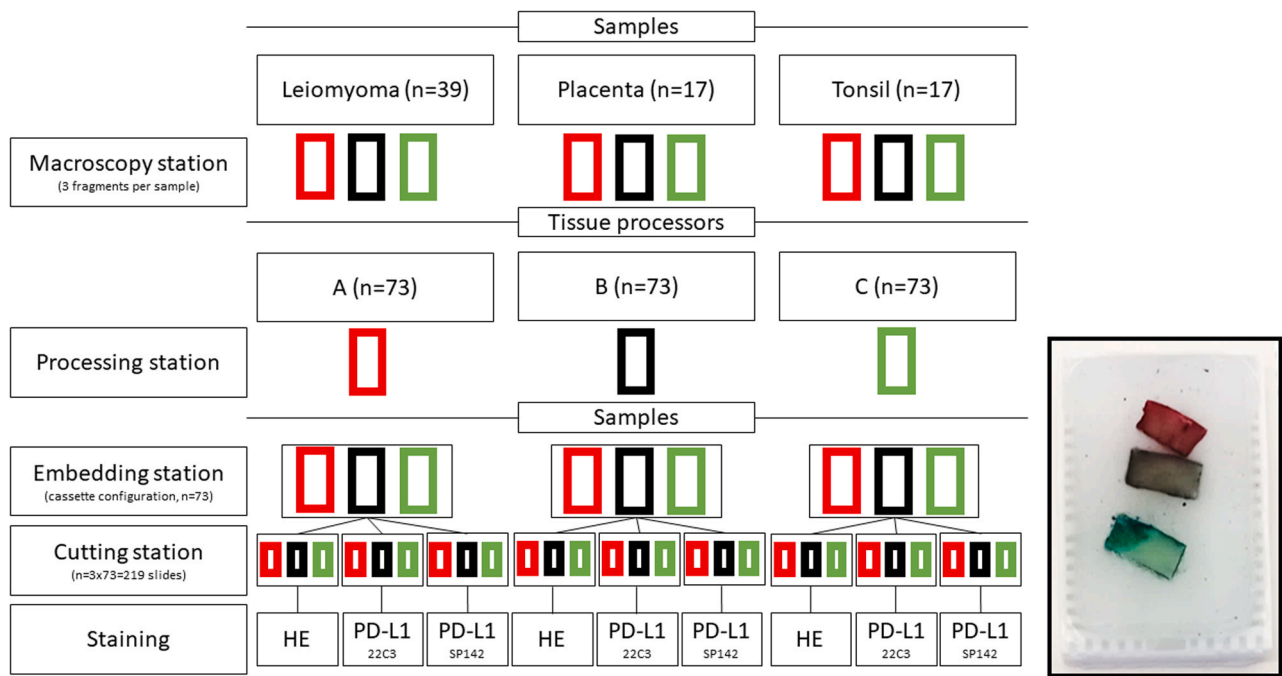
Received 7 May 2023; Received in revised form 4 June 2023; Accepted 6 June 2023

Available online 8 June 2023

0344-0338/© 2023 The Author(s).

Published by Elsevier GmbH. This is an open access article under the CC BY license

(<http://creativecommons.org/licenses/by/4.0/>).



**Fig. 1.** Scheme illustrating the methodology of the study that, while keeping the same pre and post processing variables, changed the tissue processing conditions using 3 different tissues processors - A, B and C; on the right - example of paraffin block with tissue fragments, collected from the same leiomyoma of the uterus, and processed by the different tissue processors following the code of colors A- red, B - black and C - green.

methods as well as different cutoffs that establish the eligibility for therapy. The cutoffs used to separate patients that may benefit or not from such promising therapies are sensitive to changes in the 1 % range, requiring a tight control of all phases to guaranty a reliable result [12].

As demonstrated for other immunohistochemical biomarkers, the staining obtained in a single sample may vary between different laboratories using different instruments and reagents as well as other testing conditions [13]. Proficiency testing provided by several external quality control programs are being used to harmonize the results achieved in different laboratories [14–16].

Tissue processing is one of the steps of sample preparation in the Pathology laboratory that may interfere with the antigenicity of the tissues and, eventually, contribute to the variability of the PD-L1 expression [17]. Tissue processing aims to transform tissues fixed in formalin into material suitable to be embedded into paraffin blocks. The progressive need to decrease turnaround time, the awareness for health risks associated with exposure to processing reagents and the need to improve precision, motivated the introduction of variations in the tissue processing instruments and protocols [18]. These variations to the conventional tissue processing include those that allow the use of high temperature (resistance and/or microwave), pressure, vacuum, and agitation, coupled with the use of less toxic reagents [19].

The main goal of this work is to evaluate the impact of the usage of different tissue processors in the immunohistochemical expression of two PD-L1 antibody clones (22C3 and SP142) most frequently used to predict the response to immunotherapy in cancer models.

## 2. Material and methods

In this study, carried from January 15th, 2020, to January 6th, 2021, at the Pathology Laboratory of Ipatimup, three different topographies of samples ( $n = 73$ ) were selected at the macroscopy room during the first observation: 39 uterine leiomyomas, 17 placentas without visible disease, and 17 palatine tonsils removed due to hypertrophy. The samples were fixed in 10 % neutral buffered formalin for 6–72 h. During the macroscopic observation, for each specimen, three consecutive

fragments of the same thickness, length, and width were collected ( $1,0 \times 0,5 \times 0,3$  cm each), comprehending a total of 219 fragments that included: 117 fragments of leiomyoma, 51 fragments of placenta and 51 fragments of palatine tonsils. Each of these fragments were inked with a specific color, that represented the different tissue processing instrument where the fragment would be processed according to the following code: A – red colour that corresponds to Citadel 2000™ tissue processor (EpreDia™, Kalamazoo, USA), B – black for Donatello™ series 2 tissue processor (Diapath™, Martinengo, Italy) and C – green for Pathos Delta® tissue processor (Milestone Srl, Sorisole, Italy).

Tissue processor A is a conventional one, using only resistance-heating in wax step, that uses ethanol and xylene that is known by its toxicity. Tissue processor B uses pressure and vacuum technology, agitation by bubbling and resistance-heating of ethanol and xylene-alternative reagents such as Ottix Shaper® and Ottix Plus® (Diapath™, Martinengo, Italy) with unknown composition, respectively, contributing to the low toxicity in the pathology laboratory. Tissue processor C uses pressure and vacuum, microwave, and resistance-heating technology, and uses isopropanol as a substitute of the clearing phase. All the tissue processing protocols were performed based in the manufacturer recommendations and validated internally prior to this study for internal usage, with good performance in the daily routine of our laboratory.

At tissue embedding station, the fragments of the same specimen that were processed in different tissue processors were embedded within the same paraffin block (Fig. 1). Three consecutive sections of 3  $\mu$ m from each paraffin block were obtained. The first slide was stained on the Tissue-Tek Prisma® Plus automatic stainer (Sakura™, Tokyo, Japan), by the hematoxylin and eosin (HE) technique. The other 2 slides (positively charged adhesive slides) after 20 min in the oven at 60 °C, were submitted to perform automated immunohistochemistry on the Ventana Benchmark XT™ (Ventana Medical Systems, Inc.™, Tucson, USA). The technique was performed with the OptiView DAB kit™ (Ventana Medical Systems, Inc.™, Tucson, USA), Optiview amplification Kit™ (Ventana Medical Systems, Inc.™, Tucson, USA) and two different PD-L1 primary antibodies: 22C3 PD-L1 (Agilent Technologies™, Santa Clara,

**Table 1**

Comparing tissue processors regarding the presence of artifacts in 73 HE whole slide images (WSIs) (McNemar), detected by at least one pathologist.

Tissue processors	WSIs with artifacts (n,%)	p
A versus B	28, 38.4 versus 13, 17.8	<i>p</i> = 0.001
A versus C	28, 38.4 versus 37, 50.7	<i>p</i> = 0.200
B versus C	13, 17.8 versus 37, 50.7	<i>p</i> < 0.001

USA) previously diluted (1/50) in antibody diluent OP Quanto (Epre-dia™, Kalamazoo, USA), and SP142 PD-L1 ready to use (Ventana Medical Systems, Inc.™, Tucson, USA).

All slides were scanned on the Panoramic 1000® Scanner (3DHISTECH LTD., Budapest, Hungary) at 20x (0.25 μm/pixel), using the current scanning protocol validated for primary diagnosis in wholeslide images (WSIs) currently used in our laboratory [20].

All WSIs were evaluated by two pathologists trained in the evaluation of PD-L1 (CE and SC) using the CaseViewer© software (3DHISTECH, LTD., Budapest, Hungary), blindly to the used tissue processor (pathologist could see the inked color but they did not know to which tissue processor corresponded). First, the HE images were evaluated to verify if any of the fragments had processing artifacts and if they were acceptable for diagnosis by at least one pathologist (219 results). Afterwards, the 22C3 PD-L1 and SP142 PD-L1 WSIs were evaluated. For uterine leiomyoma, PD-L1 was expected to have no expression; for placenta, PD-L1 was expected to be strongly expressed in syncytiotrophoblast cells; and in the palatine tonsils, PD-L1 was expected to be moderately to strongly expressed in most epithelial cell of the tonsil crypts, weakly to moderately expressed in macrophages in the germinal center and not expressed in most lymphocytes, as well as in the superficial layer of the epithelium. The WSIs were evaluated as follows by the two pathologists: PD-L1 expression adequacy (evaluated as YES or NO, regarding the topography of the PD-L1 expression, and considered adequate if stated by YES by at least one pathologist; staining intensity (classified as 0 (absent), or present with increasing intensities 1 + (weak intensity), 2 + (moderate intensity), 3 + (strong intensity); 219 × 2 evaluations per antibody and per tissue/topography), and presence of background non-specific staining (evaluated as YES or NO, and considered to be present if stated by YES by at least one pathologist; 219 evaluations). Regarding the management of unexpected heterogeneous intensity of staining, the pathologists classified the intensity as the most

frequent one detected in the fragment.

Appropriate positive and negative controls with known reactivity were included per batch of tested slides.

For the statistical analysis, the Statistical Package for Social Sciences (SPSS®) version 27.0.1 for Windows was used. Given the size and type of the study sample, non-parametric tests such as McNemar (MN) and Wilcoxon were used, and the level of significance was defined *p* < 0.05. Simple kappa statistics was used to evaluate the concordance among pathologists.

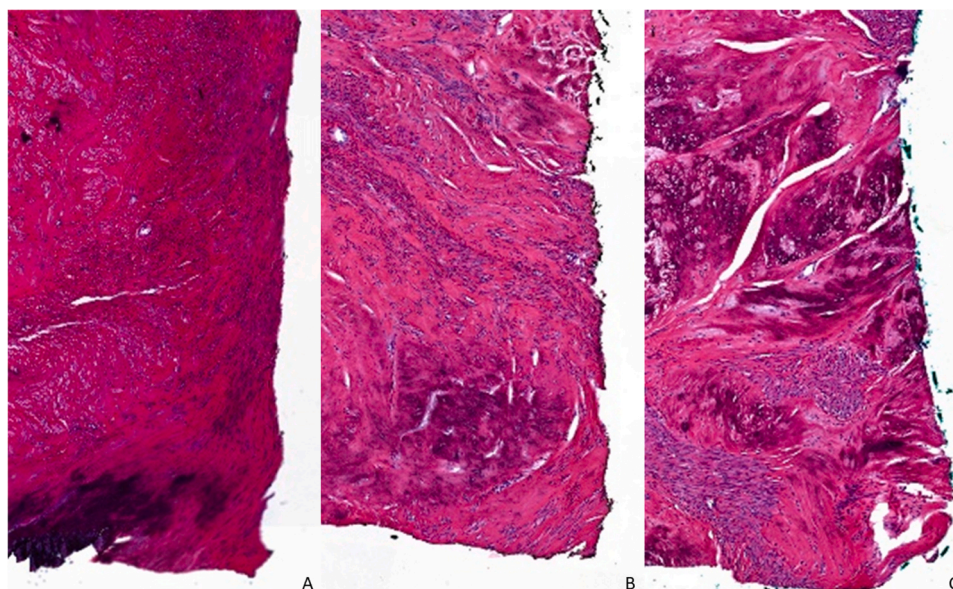
**3. Results**

Both observers reported the presence of artifacts in HE WSIs associated to processing such as decreased cell size, nuclear chromatin fading, and loss of morphological detail. The tissue processor with fewer artifacts evaluated in HE WSIs was B, in comparison with the other two tissue processors (*p* < 0.001) (Table 1). There were no significant differences between the tissue processors B and C regarding the presence of processing artifacts evaluated in HE WSIs (*p* = 0.200). Nevertheless, all 219 fragments were considered acceptable for diagnosis in HE WSIs, except one fragment processed by C and 3 fragments from the same case

**Table 2**

Whole slide images (WSIs) stained for 22C3 PD-L1 and SP142 PD-L1 after the 3 tissue processors: evaluation of background unspecific staining of PD-L1 (McNemar).

Tissue processors	22C3 PD-L1 WSIs with background (n,%)	p	SP142 PD-L1 WSIs with background (n,%)	p
A	19 out of 73, 26.0	<i>p</i> > 0.999	11 out of 71, 15.5	<i>p</i> = 0.125
versus B	versus		versus	
B	18 out of 73, 24.7		16 out of 72, 22.2	
A	19 out of 73, 26.0	<i>p</i> > 0.999	11 out of 71, 15.5	<i>p</i> = 0.109
versus C	versus		versus	
C	20 out of 73, 27.4		17 out of 71, 23.9	
B	18 out of 73, 24.7	<i>p</i> = 0.791	16 out of 72, 22.2	<i>p</i> > 0.999
versus C	versus		versus	
C	20 out of 73, 27.4		17 out of 71, 23.9	



**Fig. 2.** Illustration of the leiomyoma that had processing artifacts in all HE whole slide images (10x) after the 3 tissue processors used. A - tissue processed by A, B - tissue processed by B and C - tissue processed by C.

**Table 3**  
Study of the intensity of PD-L1 expression in placenta specimens (Wilcoxon).

Tissue processors	22C3 PD-L1 Median expression [P25-P75]	<i>p</i>	SP142 PD-L1 Median expression [P25-P75]	<i>p</i>
A versus B	3[2,3] versus 3 [3]	<i>p</i> = 0.02	1[1,2] versus 2 [1,2]	<i>p</i> = 0.02
A versus C	3[2,3] versus 3 [2,3]	<i>p</i> = 0.248	1[1,2] versus 2 [1,2]	<i>p</i> > 0.999
B versus C	3[3] versus 3 [2,3]	<i>p</i> < 0.001	2[1,2] versus 2 [1,2]	<i>p</i> = 0.007

(processed by three different tissue processors) (Fig. 2).

Regarding the slides tested with 22C3 PD-L1, all fragments were considered adequate for observation, except those 4 fragments with poor quality in the HE evaluation, mentioned above.

Concerning the evaluation of SP142 PD-L1 WSIs, the processors were not statistically different from each other regarding the adequacy for observation. From the SP142 PD-L1 WSIs, 18 out of 71 WSIs (25.4 %) processed by A, 16 out of 72 WSIs (22.2 %) processed by B and 21 out of 71 WSIs (29.2 %) processed by C, were evaluated as not adequate for observation (MN; A vs B *p* = 0.687, A vs C *p* = 0.453, B vs C *p* = 0.063). WSIs considered not adequate included those 4 with poor quality mentioned above as well as WSIs without the expected tissue pattern of expression of SP142 PD-L1. The remaining 5 WSIs had suffer from detachment of the cut from the glass slide.

The performance of the three tissue processors in inducing background non-specific staining of PD-L1 with both 22C3 and SP142 clones was similar, as summarized in Table 2.

The expression of 22C3 PD-L1 and SP142 PD-L1 was evaluated by the 2 pathologists in 39 leiomyomas. All the evaluations of both clones of PD-L1 had the expected lack of expression.

Concerning the intensity of 22C3 PD-L1 and SP142 PD-L1 expression in placenta specimens, the fragments had a more intense mean

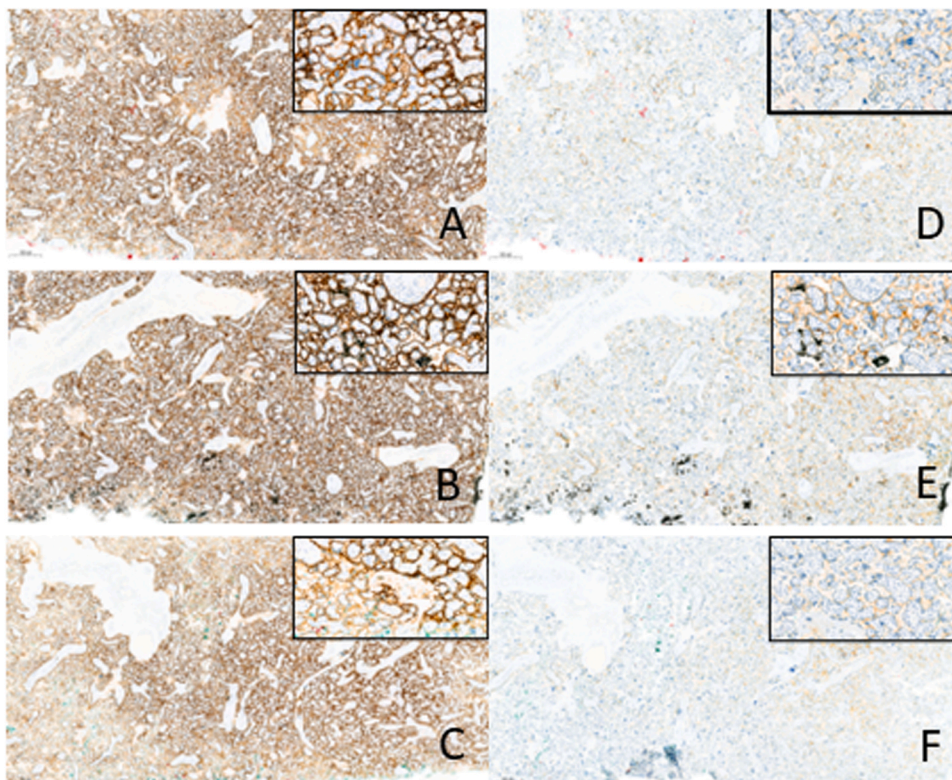
expression when processed by B than the fragments processed by A and C (Table 3) (Fig. 3).

In tonsil specimens, the 22C3 PD-L1 and SP142 PD-L1 expressions in the crypt epithelium was similar among fragments processed by the 3 tissue processors (Table 4). Less intense expression was observed in SP142 PD-L1 at the germinal centers, after tissue processing by C, in comparison with A and B (Table 4) (Fig. 4).

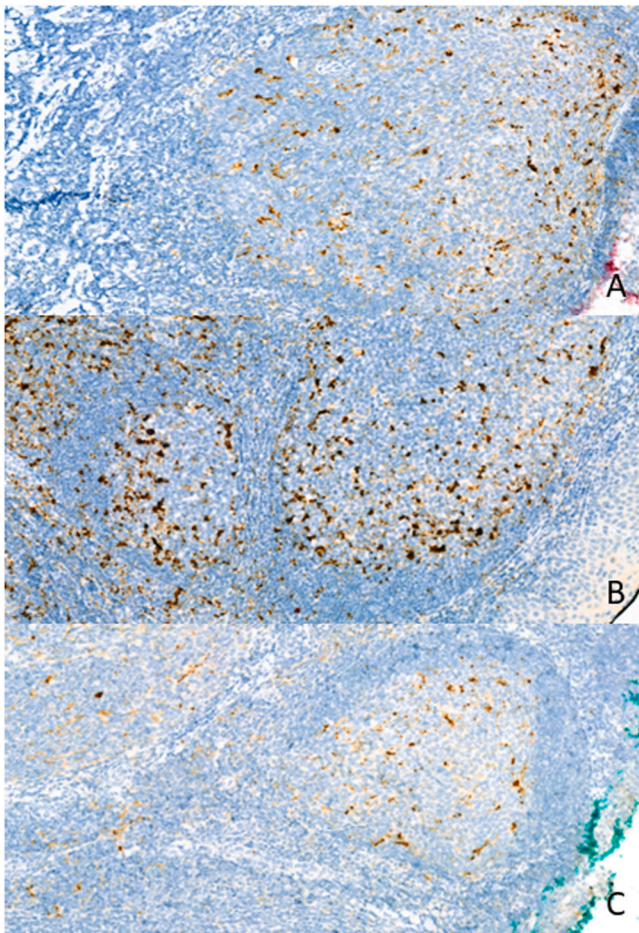
To assess interobserver variability in this study, we analyzed the concordance (simple kappa) between the two pathologists. The two pathologists agreed with each other regarding the presence of artifacts in 75.8 % (n = 166 out of 219; k = 0.336) of the HE WSIs. Of the 652 WSIs evaluated regarding their quality for diagnostic purposes, including HE, 22C3 PD-L1 and SP142 PD-L1, the two pathologists agree

**Table 4**  
Study of the intensity of PD-L1 expression in tonsil specimens – crypt epithelium and germinal centers (Wilcoxon).

Tissue processors	22C3 PD-L1 Median expression (crypt) [P25-P75]	<i>p</i>	SP142 PD-L1 Median expression (crypt) [P25-P75]	<i>p</i>
A versus B	3[3] versus 3 [2.75–3]	<i>p</i> = 0.317	3[3] versus 3[3]	<i>p</i> = 0.655
A versus C	3[3] versus 3[2,3]	<i>p</i> = 0.059	3[3] versus 3[3]	<i>p</i> = 1.000
B versus C	3[2.75–3] versus 3[2,3]	<i>p</i> = 0.257	3[3] versus 3[3]	<i>p</i> = 0.655
	<b>Median expression (germinal centers) [P25-P75]</b>	<b><i>p</i></b>	<b>Median expression (germinal centers) [P25-P75]</b>	<b><i>p</i></b>
A versus B	2[2] versus 2[2]	<i>p</i> = 0.257	3[2,3] versus 3 [2,3]	<i>p</i> = 0.527
A versus C	2[2] versus 2[1,2]	<i>p</i> = 0.090	3[2,3] versus 2 [1–3]	<i>p</i> = 0.001
B versus C	2[2] versus 2[1,2]	<i>p</i> = 0.248	3[2,3] versus 2 [1–3]	<i>p</i> = 0.001



**Fig. 3.** Representative image of a placenta case with different staining intensities after different tissue processors for both PD-L1 clones (22C3 and SP142) (2.5x and insets 20x). A to C - clone 22C3 (A - fragment processed by A with a staining intensity of 3 +; B - fragment processed by B with a staining intensity of 3 +, C - fragment processed by C with a staining intensity of 2 +), D to F - clone SP142 (D - fragment processed by A with a staining intensity of 1 +, E - fragment processed by B with a staining intensity of 2 +, F - fragment processed by C with a staining intensity of 1 +).



**Fig. 4.** Illustrative image of a tonsil case that obtained different intensities of immunohistochemical expression for SP142 PD-L1 in the different tissue processors used (20x). (A - fragment processed by A with a staining intensity of 2+, B - fragment processed by B with a staining intensity of 3+, C - fragment processed by C with a staining intensity of 1+).

with each other in 92.8 % (n = 605; k = 0.328) of the WSIs.

#### 4. Discussion

This study demonstrates, in a series of tissue controls collected from 3 topographies, that tissue processors, with their intrinsic features and reagents, have impact in the result of PD-L1 IHC, as well as in the introduction of artifacts, even if the instruments are adjusted for the routine usage in a Pathology laboratory.

If it is true that all but one set of 3 fragments of our series (probably collected from a sample with preprocessing/preanalytic deficient conditions) were considered adequate for observation, the presence of artifacts associated with processing issues was recorded as high as 50.7 %. This observation suggests that pathologists are used to tolerate a high percentage of interferences in the material set for observation, being able to ignore them while addressing the diagnosis in its complexity. This high tolerance expressed by the observers is also manifested in the difficulties in the identification of these artifacts, translated by the relatively low concordance values between observers regarding stating the presence of artifacts on HE WSIs (k = 0.336). The extraordinary capacity of the human brain in ignoring artifacts is a virtue still not reported in deep learning-based diagnostic models in digital pathology [4]. In fact, these algorithms, although representing a great hope in the community [21], are sensitive to histological artifacts that, depending on its severity, can lead to a substantial loss in models' performance (4, 23). Specifically, the processing technique has already shown to

influence cell detection and classification by artificial intelligence algorithms [22].

In this study, we also demonstrate that different PD-L1 clones exhibit different robustness in maintaining their stability of expression regardless the type of tissue processing. Of note, 22C3 PD-L1 was more frequently considered adequate for evaluation than SP142 PD-L1 that, in 29.2 % of WSIs (generated after tissue processor C) were considered not adequate for observation due to lack of the typical pattern of expression. Similarly, the intensity of PD-L1 staining was decreased in fragments processed by C for both PD-L1 clones in tonsil and placenta specimens. These observations, taken together, allow us to suggest that cases with fragment processed by C may eventually have lower percentage of PD-L1 positive cases than those processed by B, with a potential increase in false negative results. On the other hand, in this study, the occurrence of background non-specific staining and the presence of false positive results appear to be unrelated with the PD-L1 clone or the type of tissue processing. Tissue processing is a phase of the sample management that is known to interfere with tissue antigenicity name trough heating that can lead to protein denaturation [23]. A combination of heating temperature/conditions and reagents in processor C may justify the low expression of PD-L1 described above.

The progressive review of the tissue processing technology is certainly for the benefits of users, with less toxic reagents (example in B and C), and of the patients with acceleration of the process (example B and C). Nevertheless, the results of this study suggest that analytic conditions less often motive of consideration such as tissue processing, may be major culprits in the lack of consistent results of biomarkers evaluation, such as PD-L1. The variability in the technology and reagents used by each tissue processor, often multiplied by other variables in other phases of the process may significantly amplify the differences among results obtained by each laboratory. These observations support others reported in the literature [1,2] favoring the urgent need to standardize tissue processing and to review the basic chemistry associated with the biomarkers evaluation, since it has been proved to fail as a solid quantitative method [24,25]. Without the appropriate revision of the basic chemistry associated with biomarkers evaluation, the attempts to quantify immunohistochemical expression in digital images with the help of software [26] will always be fragile. Meanwhile, in laboratories with more than one type of tissue processing, is relevant to validate selectively each antibody according to each processing type. Moreover, as suggested here, tissues processed by one method may constitute inappropriate controls to IHC tests performed in tissues processed by other methods.

Ultimately, in this study, it is not possible to know if the variability of the results is due to the type of processing or due to the reagents used. Nevertheless, the tandem tissue processor plus associated reagents work as a unit and it is not recommended to exchange certain types of reagents that do not warrant the correct functioning of the instruments. Saying this, future works with robust instruments may help understanding the role of these variables independently. Another limitation of this study comprehends the lack of precision in controlling the preanalytical variables such as fixation time. In this study we cannot exclude that a certain tissue processor could perform better or not in a specific range of fixation time.

This study demonstrates the need to review and standardize the tissue processing in pathology laboratories to cope with the growing needs of precision medicine inherent quantifications and the production of high-quality material necessary for computational pathology usage.

#### Ethics approval and consent to participate

Formal ethical approval was not required for this study, as it did not involve any patient data collection or impact on patient care.

## Author contributions

MC, JV, AC, AP and CE performed study concept and design; AC, AP, MC and CE performed development of methodology and writing, review, and revision of the paper; JV, CE, SC, VN, MB, DF, TP and BN performed observation and data collection; AP and CE provided analysis and interpretation of data, and statistical analysis. All authors read and approved the final paper.

## Funding

The authors received no specific funding for this work.

## Declaration of Competing Interest

Diapath® S.p.A provided part of the reagents and instrument necessary for the execution of this work. C.E. consults for Mindpeak, 3DHISTECH and Leica. Other authors declare no conflict of interest.

## Data availability

Data generated or analysed during this study are partially included in this published article and may be provided after reasonable request.

## References

- [1] R.J. Zarbo, The unsafe archaic processes of tissue pathology, *Am. J. Clin. Pathol.* 158 (2022) 4–7.
- [2] T. Carll, C. Fuja, T. Antic, R. Lastra, P. Pytel, Tissue contamination during transportation of formalin-fixed, paraffin-embedded blocks, *Am. J. Clin. Pathol.* 158 (2022) 96–104.
- [3] H. Sadik, D. Pritchard, D.M. Keeling, F. Policht, P. Riccelli, G. Stone, K. Finkel, J. Schreier, S. Munksted, Impact of clinical practice gaps on the implementation of personalized medicine in advanced non-small-cell lung cancer, *JCO Precis Oncol.* 6 (2022), e2200246.
- [4] B. Schömig-Markiefka, A. Pryalukhin, W. Hulla, A. Bychkov, J. Fukuoka, A. Madabhushi, V. Achter, L. Nieroda, R. Büttner, A. Quaas, Y. Tolkach, Quality control stress test for deep learning-based diagnostic model in digital pathology, *Mod. Pathol.* (2021) 2098–2108.
- [5] H. Reis, R. Serrette, J. Posada, V. Lu, Y.B. Chen, A. Gopalan, S.W. Fine, S.K. Tickoo, S.J. Sirintrapun, G. Iyer, S.A. Funt, M.Y. Teo, J.E. Rosenberg, D.F. Bajorin, G. Dalbagni, B.H. Bochner, D.B. Solit, V.E. Reuter, H.A. Al-Ahmadie, PD-L1 expression in urothelial carcinoma with predominant or pure variant histology: concordance among 3 commonly used and commercially available antibodies, *Am. J. Surg. Pathol.* 43 (2019) 920–927.
- [6] H. Liu, T. Ye, X. Yang, P. Lv, X. Wu, H. Zhou, H. Lu, K. Tang, Z. Ye, Predictive and prognostic role of PD-L1 in urothelial carcinoma patients with anti-PD-1/PD-L1 therapy: a systematic review and meta-analysis, *Dis. Markers* 2020 (2020) 8375348.
- [7] M.G. McCusker, D. Orkoulas-Razis, R. Mehra, Potential of pembrolizumab in metastatic or recurrent head and neck cancer: evidence to date, *Oncol. Targets Ther.* 13 (2020) 3047–3059.
- [8] S. Ahn, K.M. Kim, PD-L1 expression in gastric cancer: interchangeability of 22C3 and 28-8 pharmDx assays for responses to immunotherapy, *Mod. Pathol.* 34 (2021) 1719–1727.
- [9] G. Brar, M.A. Shah, The role of pembrolizumab in the treatment of PD-L1 expressing gastric and gastroesophageal junction adenocarcinoma, *Ther. Adv. Gastroenterol.* 12 (2019), 1756284819869767.
- [10] E.B. Garon, N.A. Rizvi, R. Hui, N. Leighl, A.S. Balmanoukian, J.P. Eder, A. Patnaik, C. Aggarwal, M. Gubens, L. Horn, E. Carcereny, M.J. Ahn, E. Felip, J.S. Lee, M. D. Hellmann, O. Hamid, J.W. Goldman, J.C. Soria, M. Dolled-Filhart, R. Z. Rutledge, J. Zhang, J.K. Luceford, R. Rangwala, G.M. Lubiniecki, C. Roach, K. Emancipator, L. Gandhi, K.- Investigators, Pembrolizumab for the treatment of non-small-cell lung cancer, *N. Engl. J. Med.* 372 (2015) 2018–2028.
- [11] B. Vennapusa, B. Baker, M. Kowanetz, J. Boone, I. Menzl, J.M. Bruey, G. Fine, S. Mariathasan, I. McCaffery, S. Mocci, S. Rost, D. Smith, E. Dennis, S.Y. Tang, B. Damadzadeh, E. Walker, P.S. Hegde, J.A. Williams, H. Koeppen, Z. Boyd, Development of a PD-L1 complementary diagnostic immunohistochemistry assay (SP142) for Atezolizumab, *Appl. Immunohistochem. Mol. Morphol.* 27 (2019) 92–100.
- [12] E. Torlakovic, H.J. Lim, J. Adam, P. Barnes, G. Bigras, A.W.H. Chan, C.C. Cheung, J.H. Chung, C. Couture, P.O. Fiset, D. Fujimoto, G. Han, F.R. Hirsch, M. Ilie, D. Ionescu, C. Li, E. Munari, K. Okuda, M.J. Ratcliffe, D.L. Rimm, C. Ross, R. Roge, A.H. Scheel, R.A. Soo, P.E. Swanson, M. Tretiakova, K.F. To, G.W. Vainer, H. Wang, Z. Xu, D. Zielinski, M.S. Tsao, "Interchangeability" of PD-L1 immunohistochemistry assays: a meta-analysis of diagnostic accuracy, *Mod. Pathol.* 33 (2020) 4–17.
- [13] N. Arima, R. Nishimura, T. Osako, Y. Nishiyama, M. Fujisue, Y. Okumura, M. Nakano, R. Tashima, Y. Toyozumi, The importance of tissue handling of surgically removed breast cancer for an accurate assessment of the Ki-67 index, *J. Clin. Pathol.* 69 (2016) 255–259.
- [14] A. Dodson, S. Parry, B. Lissenberg-Witte, A. Haragan, D. Allen, A. O'Grady, E. McClean, J. Hughes, K. Miller, E. Thunnissen, External quality assessment demonstrates that PD-L1 22C3 and SP263 assays are systematically different, *J. Pathol. Clin. Res.* 6 (2020) 138–145.
- [15] A.H. Scheel, S.C. Schafer, Current PD-L1 immunohistochemistry for non-small cell lung cancer, *J. Thorac. Dis.* 10 (2018) 1217–1219.
- [16] C.C. Cheung, H.J. Lim, J. Garratt, J. Won, C.B. Gilks, E.E. Torlakovic, Diagnostic accuracy in fit-for-purpose PD-L1 testing, *Appl. Immunohistochem. Mol. Morphol.* 27 (2019) 251–257.
- [17] D. Otali, C.R. Stockard, D.K. Oelschlagel, W. Wan, U. Manne, S.A. Watts, W. E. Grizzle, Combined effects of formalin fixation and tissue processing on immunorecognition, *Biotech. Histochem* 84 (2009) 223–247.
- [18] R. Metgud, M.S. Astekar, A. Soni, S. Naik, M. Vanishree, Conventional xylene and xylene-free methods for routine histopathological preparation of tissue sections, *Biotech. Histochem.* 88 (2013) 235–241.
- [19] R.J. Buesa, M.V. Peshkov, Histology without xylene, *Ann. Diagn. Pathol.* 13 (2009) 246–256.
- [20] C. Eloy, J. Vale, M. Curado, A. Polonia, S. Campelos, A. Caramelo, R. Sousa, M. Sobrinho-Simoes, Digital pathology workflow implementation at IPATIMUP, *Diagnostics (Basel)* 11 (2021) 2111.
- [21] M.A. Berbis, D.S. McClintock, A. Bychkov, J. Van der Laak, L. Pantanowitz, J. K. Lennerz, J.Y. Cheng, B. Delahunt, L. Egevad, C. Eloy, A.B. Farris 3rd, F. Frassetto, R. Garcia Del Moral, D.J. Hartman, M.D. Herrmann, E. Hollemans, K. A. Iczkowski, A. Karsan, M. Kriegsmann, M.E. Salama, J.H. Sinar, J.M. Tuthill, B. Williams, C. Casado-Sanchez, V. Sanchez-Turrión, A. Luna, J. Aneiros-Fernandez, J. Shen, Computational pathology in 2030: a Delphi study forecasting the role of AI in pathology within the next decade, *EBioMedicine* 88 (2023), 104427.
- [22] S. Maruyama, N. Sakabe, C. Ito, Y. Shimoyama, S. Sato, K. Ikeda, Effect of specimen processing technique on cell detection and classification by artificial intelligence, *Am. J. Clin. Pathol.* (2023) 448–454.
- [23] D. Chafin, A. Theiss, E. Roberts, G. Borlee, M. Otter, G.S. Baird, Rapid two-temperature formalin fixation, *PLoS One* 8 (2013), e54138.
- [24] A.I. Fernandez, M. Liu, A. Bellizzi, J. Brock, O. Fadare, K. Hanley, M. Harigopal, J. M. Jorns, M.G. Kuba, A. Ly, M. Podoll, K. Rabe, M.A. Sanders, K. Singh, O.L. Snir, T.R. Soong, S. Wei, H. Wen, S. Wong, E. Yoon, L. Pusztai, E. Reisenbichler, D. L. Rimm, Examination of low ERBB2 protein expression in breast cancer tissue, *JAMA Oncol.* 8 (2022) 1–4.
- [25] S.A. Bogen, D.J. Dabbs, K.D. Miller, S. Nielsen, S.C. Parry, M.J. Szabolcs, N. t'Hart, C.R. Taylor, E.E. Torlakovic, A consortium for analytic standardization in immunohistochemistry, *Arch. Pathol. Lab Med* (2022) 584–590.
- [26] M. Salto-Tellez, J.S. Reis-Filho, Clinical trials and digital pathology-toward quantitative therapeutic immunohistochemistry and tissue hybridization, *JAMA Oncol.* 9 (2023) 168–169.